

# A novel combination of peripheral nerve blocks for arthroscopic shoulder surgery

D. Musso<sup>1</sup>, S. Flohr-Madsen<sup>2</sup>, K. Meknas<sup>3</sup>, T. Wilsgaard<sup>4</sup>, L. M. Ytrebø<sup>1</sup>  and Ø. Klaastad<sup>1</sup>

<sup>1</sup>Department of Anesthesiology, University Hospital of North Norway and UiT-The Arctic University of Norway, Tromsø, Norway

<sup>2</sup>Department of Anesthesiology, Sykehuset Sørlandet, Kristiansand, Norway

<sup>3</sup>Department of Orthopedic Surgery, University Hospital of North Norway and UiT-The Arctic University of Norway, Tromsø, Norway

<sup>4</sup>Department of Community Medicine, UiT-The Arctic University of Norway, Tromsø, Norway

## Correspondence

L. M. Ytrebø, Department of Anesthesiology, University Hospital of North Norway, N-9038 Tromsø, Norway  
E-mail: lars.marius.ytrebo@unn.no

## Conflict of interest

Concert Medical LLC provided the B-smart pressure manometers.

Submitted 2 May 2017; accepted 2 July 2017; submission 27 February 2017.

## Citation

Musso D, Flohr-Madsen S, Meknas K, Wilsgaard T, Ytrebø LM, Klaastad Ø. A novel combination of peripheral nerve blocks for arthroscopic shoulder surgery. *Acta Anaesthesiologica Scandinavica* 2017

doi: 10.1111/aas.12948

**Background:** Interscalene brachial plexus block is currently the gold standard for intra- and post-operative pain management for patients undergoing arthroscopic shoulder surgery. However, it is associated with block related complications, of which effect on the phrenic nerve have been of most interest. Side effects caused by general anesthesia, when this is required, are also a concern. We hypothesized that the combination of superficial cervical plexus block, suprascapular nerve block, and infraclavicular brachial plexus block would provide a good alternative to interscalene block and general anesthesia.

**Methods:** Twenty adult patients scheduled for arthroscopic shoulder surgery received a combination of superficial cervical plexus block (5 ml ropivacaine 0.5%), suprascapular nerve block (4 ml ropivacaine 0.5%), and lateral sagittal infraclavicular block (31 ml ropivacaine 0.75%). The primary aim was to find the proportion of patients who could be operated under light propofol sedation, without the need for opioids or artificial airway. Secondary aims were patients' satisfaction and surgeons' judgment of the operating conditions.

**Results:** Nineteen of twenty patients (95% CI: 85–100) underwent arthroscopic shoulder surgery with light propofol sedation, but without opioids or artificial airway. The excluded patient was not comfortable in the beach chair position and therefore received general anesthesia. All patients were satisfied with the treatment on follow-up interviews. The surgeons rated the operating conditions as good for all patients.

**Conclusion:** The novel combination of a superficial cervical plexus block, a suprascapular nerve block, and an infraclavicular nerve block provides an alternative anesthetic modality for arthroscopic shoulder surgery.

## Editorial comment

In this feasibility study including 20 patients, the authors present a novel combination of a superficial cervical plexus block, suprascapular nerve block, and infraclavicular nerve block for arthroscopic shoulder surgery. Results are encouraging, but need confirmation in large scale studies.

Interscalene brachial plexus block remains the gold standard for intraoperative and post-operative pain management in patients undergoing arthroscopic shoulder surgery. In expert hands, it has a very high success rate,<sup>1</sup> but may cause a wide spectrum of complications and undesired side effects.<sup>2–6</sup> The risk of neurological complications, particularly concerning the phrenic nerve,<sup>7,8</sup> has encouraged the development of alternative peripheral block methods for arthroscopic shoulder surgery.<sup>9</sup>

The shoulder joint is innervated by a few nerves: subscapular, axillary, lateral pectoral, and suprascapular nerve. The subscapular, axillary, and lateral pectoral nerve can be blocked with the infraclavicular block, while the suprascapular nerve must be blocked separately. Two nerves provide the cutaneous innervation of the shoulder: the supraclavicular and the axillary nerves. The supraclavicular nerves are not derived from the brachial plexus, but arise from the superficial cervical plexus.<sup>9–11</sup> Novel block methods should block all these nerves in order to provide effective intraoperative anesthesia and post-operative analgesia.

Several alternatives to the interscalene block have been proposed in order to avoid the effect on the diaphragmatic function, yet many of them require further confirmatory trials. In the last years some authors have proposed a C7 root block,<sup>12,13</sup> an alternative supraclavicular block limited to the distal upper extremity,<sup>14</sup> and an axillary-suprascapular block.<sup>15</sup>

We hypothesized that a combination of superficial cervical plexus block, suprascapular nerve block, and lateral sagittal infraclavicular brachial plexus block would provide intraoperative anesthesia and post-operative analgesia for patients undergoing arthroscopic shoulder surgery. To test this hypothesis we performed a feasibility study in 20 patients scheduled for arthroscopic shoulder surgery. The primary aim was the proportion of patients who could be operated under light propofol sedation, but without the need for opioids or artificial airway. Secondary aims were patients' satisfaction and surgeons' judgment of the operating conditions.

## Methods

The study was approved by the Institutional Board at the University Hospital of North Norway (registration number 0472) and registered at [www.clinicaltrials.gov](http://www.clinicaltrials.gov) (NCT02809144). The trial was performed at the University Hospital of North Norway (Tromsø and Narvik) from April to November 2016, in accordance with the Helsinki Declaration. Written informed consent was obtained from patients scheduled for arthroscopic shoulder surgery using the following inclusion criteria: age 18–70 years, BMI 20–35 kg/m<sup>2</sup> and ASA physical status 1–3. Exclusion criteria included: pregnancy, coagulation disorders, allergy to local anesthetics, atrioventricular block, peripheral neuropathy and use of anticoagulation drugs other than acetylsalicylic acid or dipyridamol.

All blocks were performed by DM with assistance from LMY. For the two-first blocks (the superficial cervical and suprascapular nerve blocks) the patients were in semilateral position with slightly elevated upper body. Subsequently the patients were supine for the infraclavicular block. All blocks were ultrasound-guided, using either a SonoSite Edge unit or a SonoSite M-Turbo (SonoSite, Inc., Bothell, WA, USA). A 50 mm linear array probe 6–15 MHz was applied for the superficial cervical and the suprascapular nerve blocks, while a C11x broadband curved array probe 5–8 MHz was used for the lateral sagittal infraclavicular block. For the two-first blocks, correct nerve identification by ultrasound was confirmed by nerve stimulator response (Stimuplex HNS 12, B. Braun AG, Melsungen, Germany). To reduce the risk of intraneural needle tip position, for all blocks, the relationship between needle and nerve was carefully observed by ultrasound. Moreover, a nerve stimulator response by a current  $\leq 0.3$  mA, 0.1 ms and 2 Hz or an injection pressure (measured by B-Smart<sup>TM</sup>; Concert Medical LLC, Norwell, MA, USA)  $\geq 103$  kPa (15 psi) defined the need for a small retraction of the needle. The initial needle insertion was counted as the first pass. An additional needle pass was defined as needle retraction of at least 10 mm prior to further needle insertion.

Standard monitoring included pulse oximetry, electrocardiogram and non-invasive blood pressure. All patients received oxygen supplementation by a nasal cannula.

### Superficial cervical plexus block

We used a slight modification of the method first described by Tran et al.<sup>16</sup> Before the insertion of the block needle, the skin was infiltrated with 1–2 ml lidocaine 10 mg/ml. The probe was placed axially, just below the midpoint of the sternocleidomastoid muscle, to visualize the intermuscular plane between the sternocleidomastoid and the scalene muscles (between the deep part of the superficial cervical fascia and the prevertebral fascia). The needle was slowly advanced from posterolateral to anteromedial in this potential space, using the in-plane technique. The patient was instructed to signal paresthesia toward the clavicle or shoulder, while receiving a current of 0.3–0.8 mA, 0.1 ms, 2 Hz. Five ml ropivacaine 0.5% was injected in the described interfascial space while trying to avoid distribution medial to the interscalene groove. Although the supraclavicular nerves can often be visualized, a systematical search for them was not done because the technique relied on injection of local anesthetic agents in the intermuscular space.

### Suprascapular nerve block

The anterior suprascapular block was first described by Siegenthaler et al.<sup>17</sup> and has since then undergone some modifications.<sup>18,19</sup> The suprascapular nerve is usually the most cranio-lateral nerve emerging from the supraclavicular plexus. Sonographically the nerve can be traced laterally in the posterior cervical triangle, deep to the omohyoid muscle, by tilting the probe incrementally steeper in the caudal direction. This ultrasonographic observation agrees with anatomical studies by Leung et al.<sup>20</sup> The local anesthetic was injected at the most lateral short-axis view of the nerve that we could obtain, with an in-plane technique, while advancing the needle from posterolateral to anteromedial. During injection we tried to avoid fluid distribution to the supraclavicular brachial plexus cluster and (more medially) to the phrenic

nerve. Electric nerve stimulation (0.3–0.8 mA, 0.1 ms, 2 Hz) served to confirm the sonographic identification of the nerve, by palpable contractions of the infra- and supraspinatus muscles. The local anesthetic dose was 4 ml ropivacaine 0.5%, as recently described by Flohr-Madsen et al.<sup>19</sup>

### Lateral sagittal infraclavicular block

A periarterial injection technique was used, slightly modified from the method described by Flohr-Madsen et al.<sup>21</sup> Usually, the dose was administered by three local anesthetic deposits. Considering the artery as a clock face with 12 o'clock ventral, the aim was to cover the artery by fluid from 3 to 11 o'clock. The needle insertion point was 0.5–1.0 cm caudal to the lower edge of the clavicle, just medial to the coracoid process. The needle was carefully advanced in the sagittal plane with the in-plane technique, between the artery and the lateral cord, tangential to the cranial aspect of the artery. The first deposit was at 6 o'clock, the second on withdrawal of the needle between 9 and 11 o'clock and the third at 3 o'clock. The latter deposit required a needle pass ventral to the artery. Total local anesthetic dose was 31 ml ropivacaine 0.75%. The volume of each injection varied depending on observed fluid distribution, but the largest volume (15–18 ml) regularly at 6 o'clock.

Total block performance time was the time from the probe was placed on the neck for the superficial cervical plexus block to final withdrawal of the block needle after the lateral sagittal infraclavicular block.

### Block assessment

Neurologic status of the upper limb and the cervical area was assessed before the blocks (baseline) and 15 and 30 min after completion of the blocks. We performed sensory testing by applying an ice cube on pre-marked points in the areas of the supraclavicular nerves, intercostobrachial, axillary, medial brachial cutaneous, musculocutaneous, medial antebrachial cutaneous, radial, median and ulnar nerves. Supraclavicular test points were at the soft spot and at the upper border of the clavicle in

the midclavicular line. The soft spot is the posterior portal used for shoulder arthroscopy. It is formed by the interval between the infraspinatus and teres minor muscles, approximately 2 cm caudal and 1 cm medial to the posterolateral tip of the acromion. The following scale was used: 3 = normal cold feeling; 2 = reduced cold feeling (hypoalgesia); 1 = no cold feeling, but feels touch (analgesia); and 0 = no cold or touch feeling (anesthesia). Muscle power was assessed using a modified seven-point scale (Table 1).<sup>22</sup> Axillary nerve block was tested by elevation of the extended upper limb in the sagittal plane. Suprascapular nerve block was tested by the force for lateral rotation of the humerus against manual resistance, while the arm was adducted and the elbow flexed at 90°. Subscapular nerve block was tested by the force for medial rotation of the humerus against manual resistance, while the arm was adducted and the elbow flexed at 90°. The other motor nerve tests were for the musculocutaneous, radial, median, and ulnar nerves.<sup>23</sup>

Block success was assessed 30 min after withdrawal of the needle upon the last of the three blocks. The superficial cervical plexus block was judged successful if the sensory score at both of its test points was 0 or 1. The suprascapular nerve block was successful if the motor score was  $\leq 2$ . The lateral sagittal infraclavicular block was successful if the axillary sensory score was 0 or 1. Patients who failed the success criteria were followed up with repeated assessments until admittance to the operation theatre. Patients # 1–7 were accepted for surgery if the sensory score was  $\leq 1$  (the supraclavicular and axillary nerves) and the motor test score was  $\leq 2$

(the suprascapular nerve). Patients # 8–20 were accepted for surgery if the sensory score was  $\leq 1$  (the supraclavicular and axillary nerves) and the motor test score was  $\leq 4$ – (the suprascapular nerve).

We recorded the incidence of adverse events including paresthesia, vessel puncture, systemic local anesthesia toxicity, Horner's syndrome, dyspnea, hoarseness, and dysphagia. To detect pneumothorax, ultrasound was used within 15 min after completed procedure.

### Intraoperative treatment

All patients were offered propofol sedation to maintain a score between  $-2$  and  $0$  on the Richmond Agitation and Sedation Scale. The protocol required that other sedatives or analgesics were not administered.

### Post-operative assessment

All patients were interviewed in the recovery room and by phone approximately 24 h after the surgery was completed. In the recovery room, post-operative nausea and vomiting (PONV), pain at rest (numerical rating scale, 1–10), medication, signs of Horner's syndrome, hoarseness, dyspnea, or dysphagia were recorded. The same questions were repeated on day one. Additionally, we asked about time to pain debut, average and maximum pain scores at rest (numerical rating scale, 1–10) and patients' total intake of analgesics. Analgesics were converted to oral morphine equivalents.

Patients' overall satisfaction score was assessed by asking them, both in the recovery room and during the follow-up telephone call, if they would like to receive the same type of anesthetic technique for a similar operation in the future. Surgeons' judgement of the operative conditions was given by the operator in the recovery room, immediately after surgery.

A priori, we assumed a block success rate of 90% with a confidence of interval of  $\pm 13\%$ . This would require a total number of 20 patients included. Descriptive characteristics are presented as mean (standard deviation), median (interquartile range and range), or number, as appropriate. The primary aim is presented as

**Table 1** Modified Medical Research Council scale of muscle power.

5	Normal power
4+	Active movement against gravity and resistance (> 50% of normal power)
4–	Active movement against gravity and resistance (< 50% of normal power)
3	Active movement against gravity
2	Active movement with gravity eliminated
1	Flicker or trace contraction
0	No contraction



proportion with 95% confidence interval. Analyses were performed using the Statistical Package for Social Sciences (SPSS) program version 23.0 for Windows (SPSS Inc., Chicago, IL, USA).

## Results

Twenty-six consecutive patients scheduled for arthroscopic shoulder surgery were screened and 20 patients fulfilled the inclusion criteria. Patient characteristics are presented in Table 2.

Patient flow chart is presented in Fig. 1. One patient (#5) had successful blocks, but felt uneasy in the beach chair position. After starting light propofol sedation, she became restless and therefore received general anesthesia. The other 19 out of 20 patients (95% CI: 85–100) underwent arthroscopic shoulder surgery with light propofol sedation, but without any need for opioids or artificial airway. Propofol dose given was 1.4 (0.4–2.6 [0.0–3.4]), median (IQR [range]) mg/kg/t. Two patients reported slight discomfort intraoperatively (numerical rating scale 1–2) located at the posterior portal (soft spot). Both were offered analgesics, but refused. None of the patients required additional local anesthetic.

Four patients did not fulfill the block success criteria at 30 min, which resulted in a block success rate of 80%. One patient (#7) failed the midclavicular superficial cervical plexus block test at 30 min, but met the success criteria 10 min later. Three patients (#8, #9, and #20) failed the SSN test. Patient #20 and patient #9

met the success criteria 45 and 90 min after the last block, respectively.

Patient #8 retained suprascapular nerve mediated muscle power score 4—up to the time of surgery. In spite of this suboptimal score, we decided to proceed to surgery. The precondition was, by the slightest intraoperative pain, to convert to general anesthesia. The patient did not experience pain during surgery and received only propofol according to the protocol.

Summary data of block performance of the three blocks are presented in Table 3. None of the patients showed sonographic signs of pneumothorax. Total block performance time was 21.8 (20.4–26.7 [15.9–34.5]), median (IQR [range]) minutes. Time from end of local anesthetic injection until start of surgery was 118 (92–150 [71–200]), median (IQR [range]) minutes. Tables 4 and 5 show the individual sensory-motor status of all patients 15 and 30 min after the blocks.

The duration of surgery was 49 (24–63 [18–85]), median (IQR [range]) minutes. Surgeons were satisfied with the working conditions in 19 of 20 patients (all except patient #5) and would recommend this novel block combination to all new patients scheduled for arthroscopic shoulder surgery.

In the post-anesthesia care unit (PACU) none of the patients suffered from nausea/vomiting, dyspnea, hoarseness, or dysphagia. One patient demonstrated temporary Horner's syndrome and another patient reported a pain score of 2 (numeric rating scale 0–10), while the others were pain free. No drugs were required. Accordingly, in the PACU all the patients were very satisfied with the regional anesthesia. Furthermore, all of them wished to receive the same regional anesthesia, should they require the same type of surgery in the future.

Patient #3 was excluded from post-operative day one data analyses because of protocol violation. This patient was given 16 mg dexamethasone i.v. intraoperatively. During the telephone interview on the first post-operative day, no patient reported PONV, dysphagia, dyspnea, or hoarseness. Time to pain debut was 12.5 (11.7–14.8 [7.6–15.6]), median (IQR [range]) hours. Average pain score at rest was 0 (0–2.3 [0–6]), median (IQR [range]). Maximum pain score was 5 (3.5–8.5 [0–10]), median (IQR [range]).

**Table 2** Characteristics of study patients scheduled for arthroscopic shoulder surgery (*n* = 19).

Age (yrs)	55.7 (11.9)
Gender (male/female)	12/7
BMI; kg/m <sup>2</sup>	26.0 (3.4)
ASA physical status (I/II/III)	6/12/1
Types of surgery (acromioplasty/supraspinatus suture/intraarticular surgery)	9/6/4
Side (right/left)	9/10

Mean (SD) or number (*n*). Continuous variables are presented as mean (standard deviation); categorical variables are presented as counts. ASA, American Society of Anesthesiologists; BMI, mass body index.

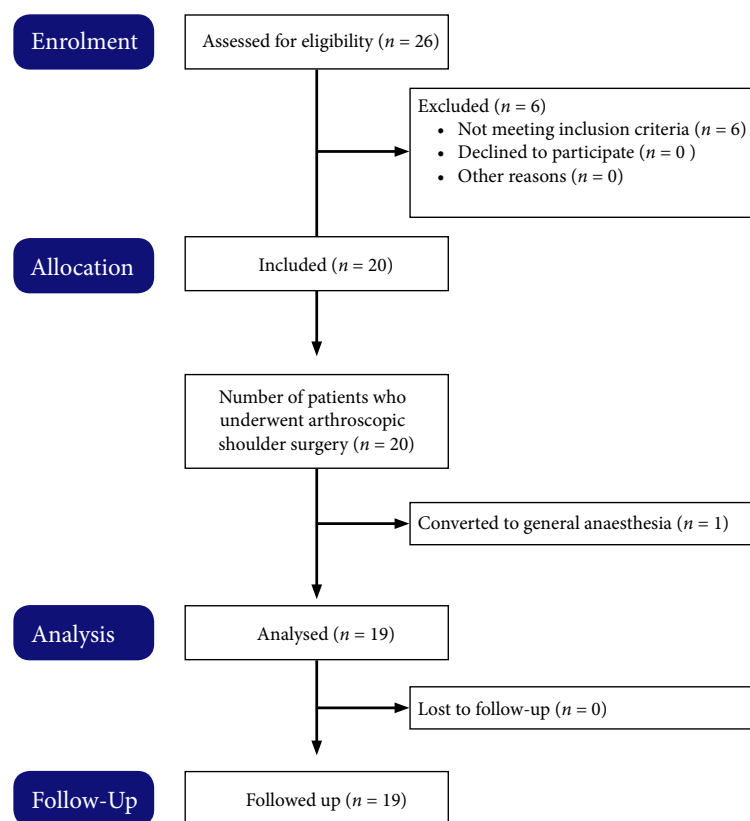


Fig. 1. CONSORT flow diagram.

**Table 3** Summary data of block performance of the three blocks ( $n = 19$ ).

	SCPB	SSNB	LSIB
Performance time (min)	6.0 (5.4–8.0 [3.6–11.2])	5.0 (3.9–7.9 [2.8–14.8])	6.5 (5.5–7.1 [4.7–12.0])
Number of needle passes ( $n$ )	1 (1–1 [1–2])	1 (1–1 [1–3])	2 (2–3 [2–3])
Paresthesia ( $n$ )	1	2	1
Vascular puncture ( $n$ )	0	0	1
Local anesthetic systemic toxicity ( $n$ )	0	0	0

Values are median (IQR [range]) or number ( $n$ ). SCPB, Superficial cervical plexus block; SSNB, Suprascapular nerve block; LSIB, Lateral sagittal infraclavicular block.

Analgesic consumption was 40 (30–60 [0–100]), median (IQR [range]) mg oral morphine equivalents during the first 24 h after surgery.

## Discussion

The study shows that this novel combination of peripheral nerve blocks is feasible and provides surgical anaesthesia and satisfactory post-

operative analgesia in patients scheduled for arthroscopic shoulder surgery.

The superficial cervical plexus block can potentially affect the brachial plexus and the phrenic nerve<sup>24</sup> if local anaesthesia penetrates the prevertebral fascia and diffuses into the interscalene groove and to the superficial aspect of the anterior scalene muscle. Nevertheless, to our knowledge there are no reports of phrenic nerve

**Table 4** Individual sensory test data 15 and 30 min after the blocks (N = 20).

Patient id	Supradlavicular nerve (soft spot)		Supradlavicular nerve (midclavicular)		Axillary nerve		Intercostobrachial nerve		Medial brachial cutaneous nerve		Musculocutaneous nerve		Medial antebrachial cutaneous nerve		Radial nerve		Median nerve		Ulnar nerve	
	15 min	30 min	15 min	30 min	15 min	30 min	15 min	30 min	15 min	30 min	15 min	30 min	15 min	30 min	15 min	30 min	15 min	30 min	15 min	30 min
	min	min	min	min	min	min	min	min	min	min	min	min	min	min	min	min	min	min	min	min
1	0	0	0	0	1	0	3	1	1	0	0	0	0	0	1	0	0	0	1	1
2	0	0	0	1	1	1	3	3	3	2	1	0	1	0	1	1	1	0	1	1
3	1	0	0	0	0	0	2	2	1	1	0	0	0	0	0	0	0	0	0	0
4	0	0	0	0	0	0	0	0	0	0	0	0	0	0	2	0	1	0	0	0
5	1	1	0	0	1	1	3	3	2	2	1	0	0	0	0	0	0	0	1	0
6	0	0	0	0	0	0	2	1	1	0	0	0	0	0	0	0	0	0	0	0
7	0	0	2	2	0	0	2	2	0	0	0	0	0	0	0	0	0	0	0	0
8	0	0	0	0	1	0	3	3	2	1	1	1	1	0	1	1	1	1	1	0
9	0	0	1	1	0	0	2	2	0	0	0	0	1	0	1	1	1	0	2	1
10	0	0	0	0	1	0	3	2	0	0	1	1	0	0	1	0	0	0	1	0
11	1	1	0	0	0	0	3	2	2	1	0	0	1	0	0	0	0	0	0	0
12	0	0	0	0	1	0	1	2	0	0	1	1	1	1	1	1	2	2	2	0
13	0	0	0	0	0	0	0	0	0	0	0	0	0	0	0	0	0	0	1	0
14	0	0	1	1	1	0	1	2	1	1	1	1	1	0	1	0	1	0	2	1
15	1	0	1	1	1	0	1	0	1	0	2	0	0	0	1	0	1	0	0	0
16	0	0	0	0	0	0	1	1	1	1	1	0	0	0	0	0	0	0	0	0
17	0	0	0	0	1	0	3	2	0	0	2	1	0	0	1	0	1	0	1	0
18	0	0	0	0	0	0	3	3	2	1	1	0	0	0	0	0	0	0	1	0
19	1	0	0	0	1	0	2	2	0	0	1	0	0	0	1	1	1	0	1	0
20	0	0	0	0	1	0	0	0	1	0	0	0	0	0	1	1	1	0	0	0

Supradlavicular test points were at the soft spot and at the upper border of the clavicle in the midclavicular line. The soft spot is the posterior portal used for shoulder arthroscopy. It is formed by the interval between the infraspinatus and teres minor muscles, approximately 2 cm caudal and 1 cm medial to the posterolateral tip of the acromion. The following scale was used: 3 = normal cold feeling; 2 = reduced cold feeling (hypoalgesia); 1 = no cold feeling, but feels touch (analgesia); and 0 = no cold or touch feeling (anesthesia).

**Table 5** Individual motor power data 15 and 30 min after the blocks ( $N = 20$ ).

Patient id	Axillary nerve		Suprascapular nerve		Subscapular/lateral pectoral nerve		Musculocutaneous nerve		Radial nerve (elbow)		Radial nerve (wrist)		Median nerve		Ulnar nerve	
	15 min	30 min	15 min	30 min	15 min	30 min	15 min	30 min	15 min	30 min	15 min	30 min	15 min	30 min	15 min	30 min
1	0	0	0	0	3	3	1	0	0	0	4–	3	4–	4–	4–	4–
2	2	0	2	1	3	0	4–	0	2	2	4–	4–	1	0	4–	4–
3	0	0	2	0	0	0	0	0	0	0	0	0	0	0	0	0
4	0	0	0	0	2	0	0	0	0	0	1	0	4–	4–	1	0
5	0	0	1	0	0	0	0	0	1	0	1	0	0	0	0	0
6	0	0	0	0	0	0	1	0	0	0	0	0	0	0	0	0
7	0	0	1	0	0	0	2	0	1	0	1	0	0	0	0	0
8	2	1	4–	4–	0	0	4–	1	0	0	4–	1	4–	4–	4–	1
9	2	1	4+	4–	4–	0	1	0	1	0	4–	1	0	4–	4–	1
10	1	0	2	1	0	0	1	0	1	1	4–	3	4–	0	4–	1
11	1	0	4–	1	0	0	0	0	0	0	0	0	0	0	1	0
12	4–	1	4–	1	4–	4–	4–	4–	1	1	4–	4–	4–	4–	4–	1
13	0	0	1	0	0	0	3	0	1	0	1	0	0	0	1	0
14	1	0	2	0	4–	0	4–	2	1	1	4–	1	5	4–	4–	1
15	2	1	2	1	3	0	4–	4–	4–	4–	4–	4–	3	0	4–	1
16	1	0	1	0	0	0	1	0	1	0	1	0	0	0	1	0
17	1	0	2	1	4–	0	4–	2	2	2	4–	1	0	0	4–	0
18	1	0	0	0	0	0	2	1	1	0	0	0	0	0	0	0
19	4–	1	4–	1	4–	0	4–	1	4–	1	4–	4–	1	0	4–	0
20	1	0	4+	4–	4–	4–	4–	4–	2	1	4–	4–	4–	0	4–	0

The nerve motor power was tested using the Modified Medical Research Council scale (Table 1). Axillary nerve: elevation of the extended upper limb in the sagittal plane. Suprascapular nerve: lateral rotation of the humerus. Subscapular/lateral pectoral nerve: medial rotation of the humerus. Musculocutaneous nerve: elbow flexion. Radial nerve: elbow and wrist extension. Median nerve: flexion of the second finger's distal interphalangeal joint. Ulnar nerve: finger abduction.



block associated with ultrasound-guided superficial cervical plexus block<sup>16,25</sup> and the incidence of this event is historically very low.<sup>26</sup> To reduce the risk of phrenic nerve block, we used a lower volume of local anesthetic than in the studies by Tran et al. and Gürkan et al.<sup>16,25</sup>

In our former study on supination of the hand after ultrasound-guided infraclavicular block, 15 patients received infraclavicular block alone and 15 combined infraclavicular and suprascapular nerve block.<sup>19</sup> Chest radiographs were taken approximately 75 min after the blocks. There were no signs of diaphragmatic paresis or paralysis. This may suggest that neither infraclavicular nor suprascapular block, or the combination of them, challenges the phrenic nerve. However, in a recent study of 32 patients receiving ultrasound-guided infraclavicular block, one patient developed hemidiaphragmatic paralysis and three patients hemidiaphragmatic paresis, as diagnosed by M-mode ultrasonography.<sup>27</sup> Based on data from these two studies, clinicians should be aware of the potential risk of infraclavicular block in patients with impaired respiratory function.

The suprascapular nerve seldom has sensory branches to the skin.<sup>28,29</sup> We therefore used a muscle power test to evaluate the suprascapular nerve block. Interestingly, surgery could be performed successfully even in patients with suprascapular nerve block failure after 30 min. Most remarkable was patient #8 who failed the suprascapular nerve test until start of surgery. We allowed this patient to be operated in accordance to protocol because of two considerations. First, there may be a significant disparity between motor power and sensory function after a peripheral nerve block.<sup>30</sup> Second, our success criterion may be too strict.<sup>18</sup> The patient did not experience any pain and received propofol only according to the protocol. In future studies we will consider using a more liberal success criterion (motor score  $\leq 4$ ) for the suprascapular nerve block.

Premedication was not administrated for two reasons. First of all, because the superficial cervical plexus block anesthetizes the supraclavicular nerves and thus the injection sites of the subsequent blocks. Secondly, our study required an accurate and timely performed neurological assessment before and after the blocks. Therefore,

we did not want any sedative or opioid to confound the interpretation of the data.

The need for three injections, change of patient's body position, and change of needle type during the procedure, make our triple block method more time consuming compared to the interscalene block.<sup>15</sup> However, in order to provide surgical anesthesia, the alternative of low volume interscalene block, requires an additional anesthesiological technique (general anesthesia, local skin infiltration or a supraclavicular nerve block), which is time consuming as well. This novel block combination might reduce costs spent on personnel and supplies, but such benefit over the interscalene block must be tested in a randomized controlled study.

The incidence of intraoperative cerebral desaturation in patients receiving general anesthesia in the beach-chair position is of great concern.<sup>6</sup> A major advantage of this novel block combination is that general anesthesia could be omitted in 19 out of 20 patients. By using only light propofol sedation, we could easily communicate with the patient and thereby directly monitor cerebral function intraoperatively.

In conclusion, this novel combination of peripheral nerve blocks provides surgical anesthesia and satisfactory post-operative analgesia for patients scheduled for arthroscopic shoulder surgery. A randomized controlled trial should be undertaken to compare this shoulder block with the interscalene block.

## Acknowledgments

None.

## References

1. Liu SS, Gordon MA, Shaw PM, Wilfred S, Shetty T, Yadeau JT. A prospective clinical registry of ultrasound-guided regional anesthesia for ambulatory shoulder surgery. *Anesth Analg* 2010; 111: 617–23.
2. Lee JH, Cho SH, Kim SH, Chae WS, Jin HC, Lee JS, Kim YI. Ropivacaine for ultrasound-guided interscalene block: 5 mL provides similar analgesia but less phrenic nerve paralysis than 10 mL. *Can J Anaesth* 2011; 58: 1001–6.
3. Riaz S, Carmichael N, Awad I, Holtby RM, McCartney CJ. Effect of local anaesthetic volume

- (20 vs 5 ml) on the efficacy and respiratory consequences of ultrasound-guided interscalene brachial plexus block. *Br J Anaesth* 2008; 101: 549–56.
4. Conroy PH, Awad IT. Ultrasound-guided blocks for shoulder surgery. *Curr Opin Anaesthesiol* 2011; 24: 638–43.
  5. Sites BD, Taenzer AH, Herrick MD, Gilloon C, Antonakakis J, Richins J, Beach ML. Incidence of local anesthetic systemic toxicity and postoperative neurologic symptoms associated with 12,668 ultrasound-guided nerve blocks: an analysis from a prospective clinical registry. *Reg Anesth Pain Med* 2012; 37: 478–82.
  6. Nielsen HB. Systematic review of near-infrared spectroscopy determined cerebral oxygenation during non-cardiac surgery. *Front Physiol* 2014; 5: 93.
  7. Hogan QH. Phrenic nerve function after interscalene block revisited: now, the long view. *Anesthesiology* 2013; 119: 250–2.
  8. Jules-Elysee K, Reid SC, Kahn RL, Edmonds CR, Urban MK. Prolonged diaphragm dysfunction after interscalene brachial plexus block and shoulder surgery: a prospective observational pilot study. *Br J Anaesth* 2014; 112: 950–1.
  9. Tran DQ, Elgueta MF, Aliste J, Finlayson RJ. Diaphragm-sparing nerve blocks for shoulder surgery. *Reg Anesth Pain Med* 2017; 42: 32–8.
  10. Borgeat A, Ekatodramis G. Anaesthesia for shoulder surgery. *Best Pract Res Clin Anaesthesiol* 2002; 16: 211–25.
  11. Aszmann OC, Dellon AL, Birely BT, McFarland EG. Innervation of the human shoulder joint and its implications for surgery. *Clin Orthop Relat Res* 1996; 330: 202–7.
  12. Renes SH, Rettig HC, Gielen MJ, Wilder-Smith OH, van Geffen GJ. Ultrasound-guided low-dose interscalene brachial plexus block reduces the incidence of hemidiaphragmatic paresis. *Reg Anesth Pain Med* 2009; 34: 498–502.
  13. Renes SH, van Geffen GJ, Rettig HC, Gielen MJ, Scheffer GJ. Minimum effective volume of local anesthetic for shoulder analgesia by ultrasound-guided block at root C7 with assessment of pulmonary function. *Reg Anesth Pain Med* 2010; 35: 529–34.
  14. Renes SH, Spoormans HH, Gielen MJ, Rettig HC, van Geffen GJ. Hemidiaphragmatic paresis can be avoided in ultrasound-guided supraclavicular brachial plexus block. *Reg Anesth Pain Med* 2009; 34: 595–9.
  15. Dhir S, Sondekoppam RV, Sharma R, Ganapathy S, Athwal GS. A comparison of combined suprascapular and axillary nerve blocks to interscalene nerve block for analgesia in arthroscopic shoulder surgery: an equivalence study. *Reg Anesth Pain Med* 2016; 41: 564–71.
  16. Tran DQ, Dugani S, Finlayson RJ. A randomized comparison between ultrasound-guided and landmark-based superficial cervical plexus block. *Reg Anesth Pain Med* 2010; 35: 539–43.
  17. Siegenthaler A, Moriggl B, Mlekusch S, Schliessbach J, Haug M, Curatolo M, Eichenberger U. Ultrasound-guided suprascapular nerve block, description of a novel supraclavicular approach. *Reg Anesth Pain Med* 2012; 37: 325–8.
  18. Rothe C, Steen-Hansen C, Lund J, Jenstrup MT, Lange KH. Ultrasound-guided block of the suprascapular nerve - a volunteer study of a new proximal approach. *Acta Anaesthesiol Scand* 2014; 58: 1228–32.
  19. Flohr-Madsen S, Ytrebo LM, Valen K, Wilsgaard T, Klaastad O. A randomised placebo-controlled trial examining the effect on hand supination after the addition of a suprascapular nerve block to infraclavicular brachial plexus blockade. *Anaesthesia* 2016; 71: 938–47.
  20. Leung S, Zlotolow DA, Kozin SH, Abzug JM. Surgical anatomy of the supraclavicular brachial plexus. *J Bone Joint Surg Am* 2015; 97: 1067–73.
  21. Flohr-Madsen S, Ytrebo LM, Kregnes S, Wilsgaard T, Klaastad O. Minimum effective volume of ropivacaine 7.5 mg/ml for an ultrasound-guided infraclavicular brachial plexus block. *Acta Anaesthesiol Scand* 2013; 57: 495–501.
  22. Paternostro-Sluga T, Grim-Stieger M, Posch M, Schuhfried O, Vacariu G, Mittermaier C, Bittner C, Fialka-Moser V. Reliability and validity of the Medical Research Council (MRC) scale and a modified scale for testing muscle strength in patients with radial palsy. *J Rehabil Med* 2008; 40: 665–71.
  23. Compston A. Aids to the investigation of peripheral nerve injuries. Medical Research Council: Nerve Injuries Research Committee. His Majesty's Stationery Office: 1942; pp. 48 (iii) and 74 figures and 7 diagrams; with aids to the examination of the peripheral nervous system. By Michael O'Brien for the Guarantors of Brain. Saunders Elsevier: 2010; pp. [8] 64 and 94 Figures. *Brain* 2010; 133: 2838–44.
  24. Shih ML, Duh QY, Hsieh CB, Liu YC, Lu CH, Wong CS, Yu JC, Yeh CC. Bilateral superficial cervical plexus block combined with general anesthesia administered in thyroid operations. *World J Surg* 2010; 34: 2338–43.

25. Gurkan Y, Tas Z, Toker K, Solak M. Ultrasound guided bilateral cervical plexus block reduces postoperative opioid consumption following thyroid surgery. *J Clin Monit Comput* 2015; 29: 579–84.
26. Pandit JJ, Satya-Krishna R, Gration P. Superficial or deep cervical plexus block for carotid endarterectomy: a systematic review of complications. *Br J Anaesth* 2007; 99: 159–69.
27. Petrar SD, Seltnerich ME, Head SJ, Schwarz SK. Hemidiaphragmatic paralysis following ultrasound-guided supraclavicular versus infraclavicular brachial plexus blockade: a randomized clinical trial. *Reg Anesth Pain Med* 2015; 40: 133–8.
28. Horiguchi M. The cutaneous branch of some human suprascapular nerves. *J Anat* 1980; 130: 191–5.
29. Ajmani ML. The cutaneous branch of the human suprascapular nerve. *J Anat* 1994; 185(Pt 2): 439–42.
30. Hemmings HC, Egan TD. Pharmacology and physiology for anesthesia: foundations and clinical application. Philadelphia, PA: Elsevier/Saunders, 2013.